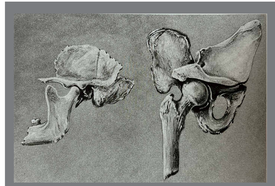

GET HIP ON CR

Altering Orientation of the Temporal Fossa Takes Place at the Pelvis and is a Major Determinant of Condylar Position

Alice Lam, DDS • Mike Cantrell, MPT, PRC • James Anderson, MPT, PRC • Nicholas Tran, BS

Introduction

Evidence has clearly shown that cranial bones are malleable(1,2,3) and that palatal malleability is an important part of cranial mobility (4). Cranial bones, including the two halves of the maxilla, move according to body position and bite configuration (5,6,7,8,9). Research and clinical evidence shows that alterations in body patterns, cranial strains, occlusion and centric relation (CR) can, and frequently do, affect one another (10,11,12,13,14). Therefore, altering the position of the pelvis and hips alters the orientation of the temporal fossa, a major determinant of condylar position. This emerging understanding of fossa mobility challenges the current definition of CR and the link between body patterns and cranial strains opens up new opportunities for advancing clinical care in occlusion, TMD, and airway science.

Problem

Centric Relation (CR) traditionally focuses on the mandibular condylar position within the temporal fossae. What is not taken into account in the definition is the mobility and position of the temporal fossae. The literature suggests there is a potent influence exerted on the temporal fossae from the rest of the body. CR in its current definition completely overlooks the body and the body's influence on temporal fossa position, and is therefore potentially incomplete.

Hypothesis

1. There is potential to see changes in both Centric Relation and body position by cutting a lingual maxillary retaining wire.
2. Position and mobility of both sides of the maxilla affects temporal fossa position.
3. Position and mobility of both sides of the maxilla affects body position.
4. Inversely, body position can also affect maxillary position, cranial strain or temporal fossa position.
5. The current definition of Centric Relation is incomplete.

Methods

In both patients A and B examiners did the following:

1. Took Centric Relation (CR) bite records and mounted scanned and printed models on semi-adjustable articulator. Scanned bite in Adapted Centric Posture (ACP) on digital scanned models.
2. Documented objective measurements of body position including occlusal grounding performance, cervical alignment, thoracic alignment and pelvic alignment.
3. Cut the lingual maxillary retaining wires between tooth 8 & 9.
4. Took new CR bite records and mounted scanned and printed models on semi-adjustable articulator. Scanned new bite in ACP on digital scanned models.
5. Documented new objective measurements of body position including occlusal grounding performance, cervical alignment, thoracic alignment and pelvic alignment.

References

1. Ueno T, Ballard RE, Macias BR, Yost WT, Hargens AR. Cranial diameter pulsations measured by non-invasive ultrasound decrease with tilt. Aviat Space Environ Med. 2003 Aug;74(8):882-5. PMID: 12924766.
2. Oleski SL, Smith GH, Crow WT. Radiographic evidence of cranial bone mobility. J Craniomandib Pract. 2002;20(1):34-38.
3. Crow WT, King HH, Patterson RM, Giuliano V. Assessment of calvarial structure motion by MRI. Osteopath Med Prim Care. 2009;3:8. Published 2009 Sep 4.
4. Harari D, et al. The effect of mouth breathing versus nasal breathing on dentofacial and craniofacial development in orthodontic patients. Laryngoscope. 2010 Oct; 120(10):2089-2093.
5. Ole E, Horiuchi M, et al. Effects of occlusal contact and its area on gravity fluctuation. Angle Orthod. 2010 May; 80(3):540-546.
6. Rothbart BA. Vertical facial dimensions linked to abnormal foot motion. J Am Podiatr Med Assoc. 2008 May-Jun;98(3):189-96. doi: 10.7547/0980189. PMID: 18487592.
7. Ohlendorf D, Seebach K, et al. The effects of a temporarily manipulated dental occlusion on the position of the spine: a comparison during standing and walking. Spine J. 2014 Oct 1; 14(10):2384-91.
8. Yoshino G, Higashi K, et al. Changes in weight distribution at the feet due to occlusal supporting zone loss during clenching. Cranio. 2003 Oct; 21(4):271-278.
9. Rothbart BA. Prescriptive proprioceptive insoles and dental orthotics change the frontal plane position of the atlas (C1), mastoid, malar, temporal, and sphenoid bones: a preliminary study. Cranio. 2013 Oct;31(4):300-8. doi: 10.1179/crn.2013.31.4.008. PMID: 24308104.
10. Valentino B, Fabozzo A, et al. The functional relationship between the occlusal plane and the plantar arches - An EMG study. Surg Radiol Anat. 1991; 13:171-174.
11. Ling N, Koenig J, Shapiro PA, Shapiro G, Trask C. A quantitative assessment of respiratory patterns and their effects on dentofacial development. Am J Orthod Dentofacial Orthop. 1990 Dec;98(6):523-32.
12. Korbmacher H, Koch L, et al. Associations between orthopaedic disturbances and unilateral crossbite in children with asymmetry of the upper cervical spine. Eur J Orthod. 2007 Feb; 29(1):100-104.
13. Bindayel NA. The impact of postural changes on dental occlusion. Pakistan Oral & Dental Journal. 2017; 37(4):583-588.
14. Marchena-Rodriguez A, Morena-Morales N, et al. Relationship between foot pressure and dental malocclusions in children aged 6 to 9 years. Medicine. 2018; 97:19.

15. Schematic illustrations (©) J. Anderson and M. Cantrell. Photograph source www.eoline.com

RIGHT Lateralized Posture Pattern

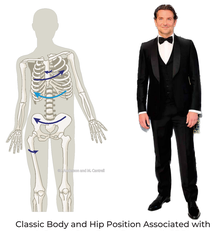

Classic Body and Hip Position Associated with L Cranial Side Bend Rotation (L SBR)

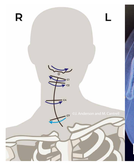

Frontal and Transverse Plane View of the Neck

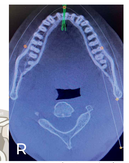

Representative Example of Transverse Plane Atlas Rotation

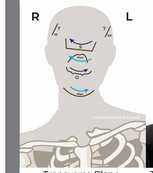

Transverse Plane View of Cranial Bones

Typical Facial Presentation of Left Side Bend Rotation

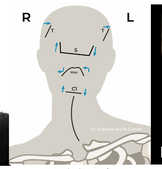

Frontal Plane View of Cranial Bones

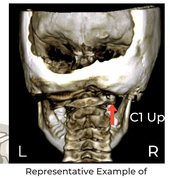

Representative Example of Frontal Plane Atlas Flexion

R & L Temporal Bone Sagittal Motion with L SBR (R Fossa Directed Forward and L Directed Backward)

LEFT Lateralized Posture Pattern

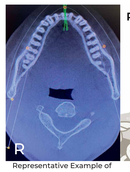

Representative Example of Transverse Plane Atlas Rotation

Frontal and Transverse Plane View of the Neck

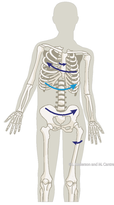

Classic Body and Hip Position Associated with R Cranial Side Bend Rotation (R SBR)

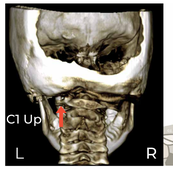

Representative Example of Frontal Plane Atlas Flexion

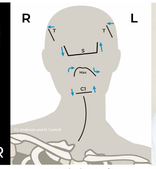

Frontal Plane View of Cranial Bones



Typical Facial Presentation of Right Side Bend Rotation

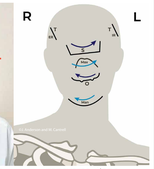

Transverse Plane View of Cranial Bones

R & L Temporal Bone Sagittal Motion with R SBR (R Fossa Directed Backward and L Directed Forward)

PATIENT A

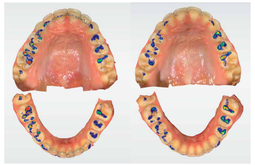

ACP With Lingual Retention Wire

ACP After Lingual Retention Wire Removal

1st CR Contact With Lingual Retention Wire

1st CR Contact After Lingual Retention Wire Removal



PATIENT B

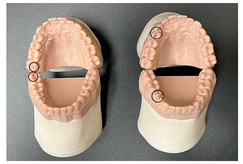

1st CR Contact With Lingual Retention Wire

1st CR Contact After Lingual Retention Wire Removal

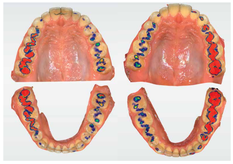

ACP With Lingual Retention Wire

ACP After Lingual Retention Wire Removal

Results

Patient A

	Before	After	Description
1st CR	3/30	5/28	Centric Relation changed
ACP	3/30	14/19	ACP changed from right to left
Occlusal Grounding	Right	Even	Right sided occlusal contact changed to be balanced
Mid Cervical Rotation	Left 10° Right 30°	Left 30° Right 30°	Right sided transverse neck alignment changed to neutral
Mid Cervical Lat Flexion	Left 25° Right 15°	Left 30° Right 30°	Right sided frontal neck alignment changed to neutral
Shoulder Int Rotation	Left 70° Right 40°	Left 85° Right 80°	Air expanded into right chest
Horiz Shoulder Abduct	Left 55° Right 90°	Left 90° Right 90°	Right rotated sternal and rib cage posture changed to neutral
Lumbo-pelvic-hip Rotation	Left 40° Right 70°	Left 70° Right 70°	Right rotated pelvis changed to neutral
Hip Adduction	Left + Right -	Left - Right -	Right rotated pelvis changed to neutral

Patient B

	Before	After	Description
1st CR	2/31	5/28	Centric Relation changed
ACP	Right	Left	ACP changed from heavy right to heavy left
Occlusal Grounding	Right	Left	Right sided occlusal contact changed to the left
Mid Cervical Rotation	Left 25° Right 10°	Left 30° Right 25°	Left sided transverse neck alignment changed to neutral
Mid Cervical Lat Flexion	Left 15° Right 25°	Left 30° Right 25°	Left sided frontal neck alignment changed to neutral
Shoulder Int Rotation	Left 55° Right 65°	Left 85° Right 85°	Air expanded primarily into left chest, and also right chest
Horiz Shoulder Abduct	Left 75° Right 25°	Left 85° Right 75°	Left rotated sternal and rib cage posture changed to neutral
Lumbo-pelvic-hip Rotation	Left 60° Right 30°	Left 65° Right 50°	Left rotated pelvis changed to neutral
Hip Adduction	Left - Right +	Left - Right -	Left rotated pelvis changed to neutral

Conclusion

Based on objective data collected on patient A and B, pre- and post-removal of maxillary bonded lingual retention wire, we can conclude the following: 1) Maxillary cranial bones do move, 2) "Strain" of the left and right maxillary bones, may result in altered position and "strain" at the sphenoid and temporal bones and 3) Movement of temporal bones directly affects centric relation and subsequently dental occlusion. 4) Increased left or right occlusion can lateralize the body center of mass into the left or right hemisphere, respectively. 5) Shifting and rotation of the center of mass affects neck position in the frontal and transverse plane, which can alter rotation of the occiput and directly affect temporal fossae position. 6) Occipital position and neck orientation create an obligatory lateralization of the center of mass to the left or right hemisphere. 7) Obligatory cranial and neck positioning as a result of occlusal drive can limit ribcage and diaphragmatic function, which can easily drive the pelvis into one hemisphere or the other through unilateral hyperactivation of the diaphragm and associated psoas muscle.

In the final analysis, if the pelvis is unilaterally oriented due to position of feet or asymmetric activity of the muscles of the pelvic diaphragm, then the resultant obligatory movements of the center of mass can drive occlusion and CR from the "bottom up". Therefore, it can logically be concluded that there is then a bi-directional relationship between CR and the position of the restricted body and hip pattern with the case studies above.

Clinical Significance

Clinical occlusal changes — whether indirectly by adjustments on splints or directly on occlusion via equilibration, restorations, orthodontics, or orthognathic surgery — have significant effects beyond the head and neck. These changes in occlusion commonly influence the position and orientation of both fossa of the temporal bones. This cranial bone alteration induces a cascading series of positional changes on the rest of the body posture. This bi-directional effect of the bite changing the body and the body changing the bite challenges the repeatability of CR in its current definition. ***CR apparently changes as the posture and position of the body below it changes.*** Therefore, the comprehensive dentist should take into account each individual's uniquely acquired body posture and its associated cranial strain patterns in order for CR to truly be repeatable and stable long-term. "To get hip on CR", re-imagining its definition will expand the role of dentistry in the world of integrative medicine.